

Testicular Toxicity Induced by Deltamethrin in Albino Mice

Asma Rashid¹, Asmatullah², Nabiha Zara¹ and Chaman Ara^{2*}

¹Department of Zoology, Govt Science College, Wahdat Road, Lahore, Pakistan

²Department of Zoology, University of the Punjab, Lahore, Pakistan

Abstract.- The objective of this study was to investigate the toxic potential of deltamethrin on the development of testis in mice. The histopathological changes induced by deltamethrin were assessed in two groups. Different concentrations of deltamethrin 0.00, 3.00 and 5.00 µg/g BW were used repeatedly for 15 and 30 days. After dosing mice were acclimatized for some days. The testes were recovered at 45th day from treatment. Histological examinations revealed significant alterations in the testes of all dose groups. Histological abnormalities observed were hyalinization, vacuolization, exfoliated spermatocytes, dilation and tubular deformity, tubular destruction and atrophy, cellular vacuolated degeneration, apical sloughing and multilayered seminiferous epithelia with late spermatids lining the lumen of the seminiferous tubules in the testis. The observed pathological changes were dose concentration and exposure time duration dependent. It is concluded that the concentrations of deltamethrin used during the present study proved toxic in mice.

Keywords: Deltamethrin, pyrethroid toxicity, histopathology, murine testes.

INTRODUCTION

Deltamethrin [(S) alpha-cyano-3-phenoxy-benzyl-(1R)-cis-3-(2,2-dibromovinyl)-2,2-dimethyl-ethylpropane-carboxylate], a type II pyrethroid, is widely used in pest control of agriculture and forestry because of its high activity against a broad spectrum of insects and pests. It is commonly used for the control of ectoparasites in domesticated animals and poultry. It is used as an alternative pesticide in malaria control program in India and other developing countries. It is reported to be most toxic, as it is neither fully metabolized nor quickly detoxified and therefore creates serious problems of residue accumulation especially in fatty tissues (Ansari and Razdan, 2001; Csillik *et al.*, 2000; Erdogan *et al.*, 2004; Jana-Kara *et al.*, 1995; Pham *et al.*, 1984; Rehman *et al.*, 2006; Yadav *et al.*, 2001).

The mode of action of deltamethrin is to interact with ion channels on the axons of target species. The basic metabolic reactions are cleavage of ester bonds by oxidation and/or hydrolysis followed by oxidation of released acid and alcohol moieties. The acid moiety is transformed into conjugates chiefly in the form of glucuronide,

excreted in urine and hydrolyzed by liver microsomal enzymes (Anand *et al.*, 2005; Hayes and Laws, 1990). Deltamethrin also produces a complex poisoning syndrome and acts on a wide range of tissues. They give sodium tail currents with relatively long time constants, which may be the reason of their ability to act on the whole range of excitable tissues (Hayes and Laws, 1991).

Previous studies have focused the possible role of deltamethrin on decreased sperm production and potentially cryptorchidism (Gray *et al.*, 1989; Gustafson and Donahoe, 1994; Jensen *et al.*, 1995; Sharpe and Skakkebaek, 1993; McLanchlan, 1998; Toppari *et al.*, 1996). There are different reports showing a trend towards decreasing sperm quality in men over the past five decades (Auger *et al.*, 1995). Due to the relatively short period of time taken for this trend to occur, it is believed that decreasing sperm quality is the result of environmental rather than genetic factors (Giwerzman *et al.*, 1993)

In this study the effect of exposure to deltamethrin has been studied on histological structures of murine testes, with an objective to extrapolate these results to humans.

MATERIALS AND METHODS

Experimental animals

Adult males approximately 4-5 week old Swiss Webster strain of albino mice, *Mus musculus*, were obtained from Veterinary Research Institute,

* Corresponding author: dr.chamanara@yahoo.com
0030-9923/2012/0005-1349 \$ 8.00/0
Copyright 2012 Zoological Society of Pakistan

Lahore. Animals were checked for external signs of injury or disease. All animals were kept in cages (14×10×7)" in controlled environmental conditions in the form of 12 hour light/dark cycles, temperature 27±2°C and relative humidity 40-55%.

Test chemicals and dose preparation

Deltamethrin (2.5 EC) prepared by Redsum Group, with Reg No. Generic/DPP/2002 (1236) was used in this experiment. LD50 value for mice has already been determined as 21-34 mg/kg (The Agrochemicals Handbook, 1983). Two sub lethal doses were prepared as D-I and D-II by dissolving 3.00 and 5.00µg/g BW of the insecticide, respectively in corn oil. Both doses were daily administered orally to these animals for two and four week's period.

Procedures

Mice were randomly distributed in one control and two experimental groups in 3 cages, each with six mice. The control group received only 0.1 ml of corn oil daily for 45 days. From amongst experimental groups, one (Group D-I) received a daily dose of 3.00 µg/g BW for 30 days, while the second group (D-II) received a daily dose of 5.00µg/g BW for 15 days. These doses were administered orally as 0.1 ml with 1 ml glass syringe. The animals were slaughtered under ether anesthesia, 24 h in the control, 15 days in DI and 30 days in DII after administration of last dose. By surgical incision, the testes were taken out of the body. The above mentioned protocols were used under approved animal treatment conditions of medical ethics committee of Punjab University, Lahore, Pakistan.

Histopathological analysis

Testes samples collected from all groups were immediately fixed in Bouin's fixative for 48 hr and then were preserved in 70% alcohol at room temperature. They were processed for paraffin sections (Spencer and Bancroft, 2008). The fixed tissue was routinely processed, embedded in wax and then 5µ thick transverse sections were studied under light microscope after staining with Haematoxylin and Eosin.

RESULTS

The control group (receiving only corn oil)

Normal histological structures of the testis were observed in the control group. Each seminiferous tubule was clearly lined with germinal epithelium. All types of spermatogenic cells: spermatogonia appeared in their normal shape: primary spermatocytes, spermatids and mature spermatozoa were observed. Mature spermatozoans were with their distinguished tails filled the lumen of seminiferous tubules. Sertoli and Leydig cells with regular shapes were observed (Fig. 1A, E).

Histopathological changes in mice group D-I (3.00µg/g BW)

In comparison to the control group severe testicular damages induced by deltamethrin were found in group D-I. These defects included; vacuolated degeneration of the spermatogenic cells, presence of necrotic cells inside the degenerative tubule, aspermatogenesis (Fig.1D), edema between the seminiferous tubule and hyalinization inside the tubule (Fig.1D), increase in apical sloughing (Fig.1B) Separation of spermatogenic cells from the germinal epithelial membrane (Fig.1C), exfoliation of spermatocytes in the lumen of some tubule (Fig.1B). Severe destruction of seminiferous tubule with multiple rupture of the germinal epithelial layers (Fig.1D). Tubular deformation (Fig.1D), Exfoliation of spermatocytes (Fig.1D), Rupture of germinal layer (Fig.1D). Severe tubular deformity associated with tubular rupture and complete spermatogenic cells degeneration (Fig.1D) were also observed.

Histopathological changes in mice group D-II (5.00µg/g BW)

Testis of mice treated under D-II group showed various anomalies during their development. There were multiple signs of vacuolization and cell necrosis with sloughing of epithelium of the tubule (Fig.1H). Decrease in number of spermatogenic cells (Fig.1C), exfoliation of spermatocytes (Fig.1F). In some specimen the intertubular tissue became hyalinized and thickened (Fig.1G). The spermatogenic cells were markedly reduced and majority of spermatocytes and

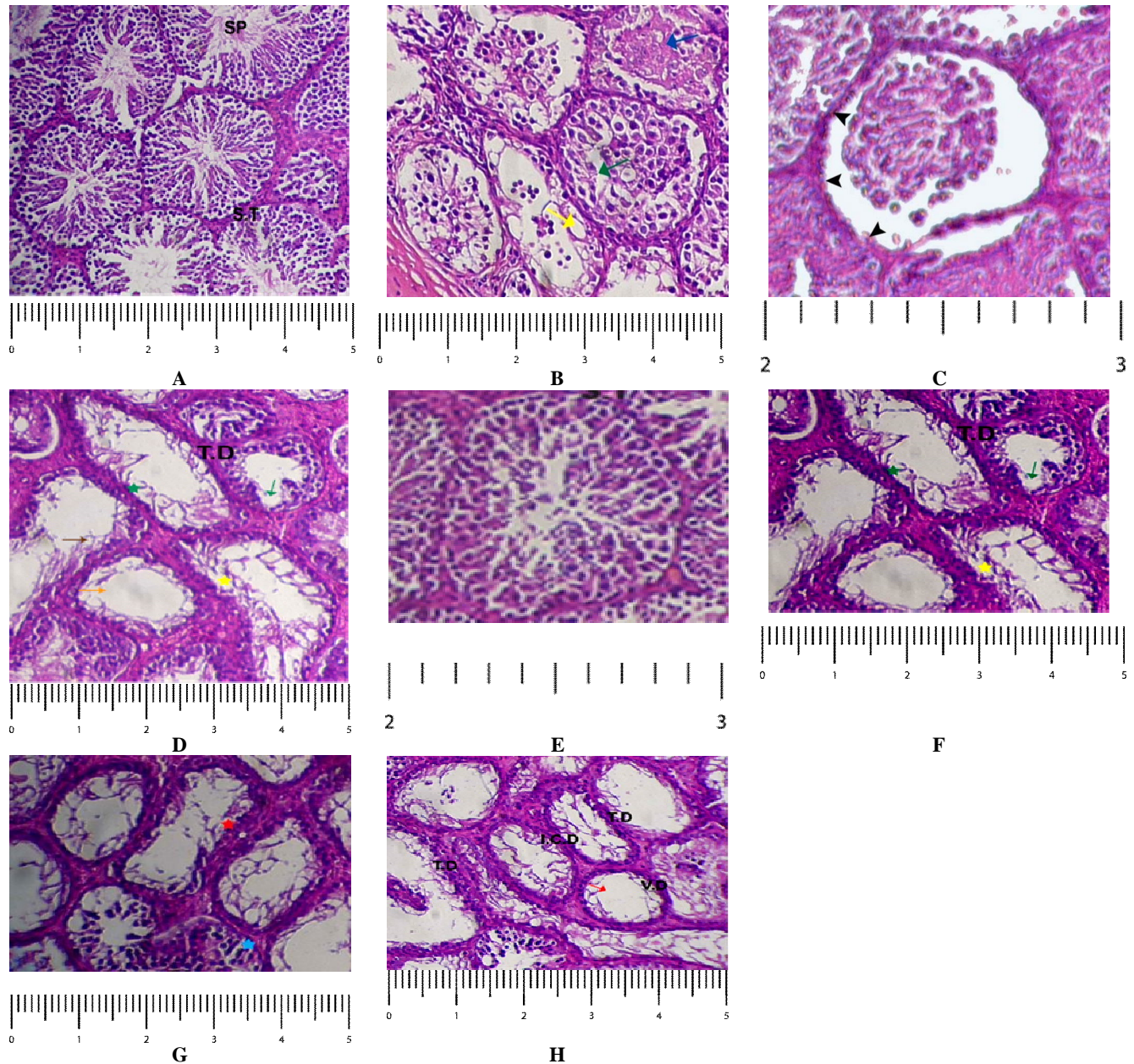


Fig. 1. Histological structure of murine testes after treatment with deltamethrin with $3\mu\text{g/g}$ B.W for 30 days (B, C, D) and $5\mu\text{g/g}$ B.W for 15 days (F, G, H) A and E are controls. Figure show seminiferous tubules (S.T), sperms (SP), exfoliation of spermatocytes (green arrow), apical sloughing (blue arrow), vacuolization (yellow arrow), separation of spermatogenic cells from germinal epithelium (head arrow), tubular deformation (T.D), rupture of germinal layer (yellow star), aspermatogenesis (brown arrow), edema between the seminiferous tubule, hyalinization inside the tubule (orange arrow), absence of spermatocytes (red star), degeneration of interstitial cells (sky blue star), vacuolated degeneration (V.D), and interstitial cells degeneration (I.C.D).
Stain: Hematoxylin & eosin.

spermatids became degenerated (Fig.1G), increase in apical sloughing (Fig.1B), exfoliation of

spermatocytes in the lumen of some tubules (Fig.1B).

DISCUSSION

Histopathological changes have been widely used as significant biological markers for environmental pollutants toxicity (Bhuiyan *et al.*, 2001; Hinton *et al.*, 1992; Meyers and Hendricks, 1985). The present study reported the testicular toxicity of deltamethrin. Various testicular damages were observed during this histological study, which revealed that deltamethrin caused reduction in spermatogenic cells, exfoliation of spermatocytes and in some cases complete spermatogenic cells degeneration. Several other anomalies such as severe deformity in seminiferous tubules, rupture of germinal epithelial layer surrounding the tubule, tubular atrophy, aspermatogenesis, vacuolization, cell necrosis along with apical sloughing, degeneration of spermatocytes and spermatids, hyalinization in intertubular tissues, Sertoli and Leydig cell degeneration and multilayered seminiferous epithelia with late spermatids lining the lumen of seminiferous tubules were also seen in the experimental groups. The recorded symptoms were similar to those reported in previous studies on rats testicular toxicity (Clos *et al.*, 1994; Hernandez *et al.*, 2006; Turner, 2002).

Abdel-Khalik *et al.* (1993) recorded significant decrease in the weight of testes, seminal vesicle and prostate glands by oral administration of deltamethrin to male albino rats for 65 consecutive days at the dose level of 1 or 2 mg /kg. Significant decreases were also noted in sperm cell concentrations, percentage of live cells and sperm motility. An increase in the percentage of sperm abnormalities was also seen. Deltamethrin is also characterized for the production of testicular apoptosis in male rats. It was found that administration of deltamethrin (1mg/kg daily for 21 days) to male rats results into testicular apoptosis. Histopathological examination of testicular tissue sections showed that apoptosis was confined to the basal germ cells, primary and secondary spermatocytes. Sertoli cell vacuoles were also seen, which indicates the reason for the suppression of spermatogenesis (El-Gohary *et al.*, 1999).

Yao and Wang (2008) reported that deltamethrin can reduce sperm count and motility. It also causes deformity of the sperm head, increases

the count of abnormal sperm, damages sperm DNA and induces its aneuploidy rate, as well as affects sex hormone levels and produces reproductive toxicity. These findings are in accordance with the current studies. Synthetic pyrethroids, deltamethrin are proven to be endocrine disruptors, which can increase the oestrogenic load in the body that exert negative feedback on FSH secretion. Reduced FSH secretion negatively effect male sexual development by reducing Sertoli cell multiplication, decreased sperm production and, potentially cryptorchidism (Gray *et al.*, 1989; Gustafson and Donahoe, 1994; Jensen *et al.*, 1995; McLanchlan, 1998; Sharpe and Skakkebaek, 1993; Toppari *et al.*, 1996).

It is concluded that the deltamethrin is severely toxic in male albino mice, which may be equally harmful to the male reproductive health. Thus the use of this particular insecticide having multitudes of systemic and developmental toxicological effects should be minimized and/or appropriate care methods should be involved for its handling. It must be used under strict safety measures. Domestic use of deltamethrin should also be minimized as it is used as repellent for mosquitoes, for the control of ectoparasites in domesticated animals. Thus by minimizing its use it may be possible to get rid of its harmful effects particularly an agricultural country like Pakistan.

ACKNOWLEDGEMENT

The authors are grateful to the Chairman, Department of Zoology, University of the Punjab for providing necessary research facilities.

REFERENCES

- ABDEL-KHALIK, M.M., HANFY, M.S. AND ABDEL-AZIZ, M.I., 1993. Studies on the teratogenic effects of deltamethrin in rats. *Dtsch. Tierarztl. Wochenschr.*, **100**: 142-143.
- AURGER, J., KUNTSMANN, J. M., CZYGLIK, F. AND JOUANET, P., 1995. Decline in semen quality among fertile men in Paris during the past 20 years. *New Engl. J. Med.*, **332**: 281-285.
- ANAND, S.S., BRUCKNER, J.V., HAINES, W.T., MURALIDHARA, S., FISHER, J.W. AND PADILLA, S., 2005. Characterization of deltamethrin metabolism by rat plasma and liver microsomes, *Toxicol. appl. Pharmacol.*, **225**: 120-126.
- ANSARI, M.A. AND RAZDAN, R.K., 2001. Concurrent

- control of mosquitoes and domestic pests by use of deltamethrin-treated curtains in the New Delhi Municipal Committee, India. *J. Am. Mosquito Contr. Assoc.*, **17**: 131-136.
- BHUIYAN, A., NESA, B. AND NESA, Q., 2001. Effects of Sumithion on the histological changes of spotted murrel, *Channa punctatus*. *Pak. J. Biol. Sci.*, **4**: 1288-1290.
- CSILLIK, B., FAZAKAS, J., NEMCSÓK, J. AND KNYIHÁRCSILLIK, E., 2000. Effects of the pesticide dektanethrine on the Mauthner cells of Lake Balaton fish. *Neurotoxicology*, **21**: 343-52.
- CLOS, M., RAMONEDA, M. AND GRACIA, G., 1994. Modification of testicular cytochrome P-450 after fenitrothion administration. *J. Gen. Pharmacol.*, **25**: 499-503.
- ERDOGAN, S., ZEREN, E.H., EMRE, M., AYDIN, O. AND GUMURDULU, D., 2004. Pulmonary effects of deltamethrin inhalation: an experimental study in rats. *Ecotoxicol. Environ. Safety*, **63**: 318-323.
- EL-GOHARY, M., AWARA, W.M., NASSAR, S. AND HAWAS, S., 1999. Deltamethrin-induced testicular apoptosis in rats: the protective effect of nitric oxide synthase inhibitor. *Toxicology*, **132**: 1-8.
- GRAY, L.E., FERREL, J., OSTBY, J., REHNER, G., LINDER, R., COOPER, R., GOLDMAN, J., SLOTT, V. AND LASKEY, J., 1989. A dose response of analysis methoxychloro-induced alterations of reproductive development and function in rat. *Fundam. appl. Toxicol.*, **12**:92-108.
- GUSTAFSON, M.L. AND DONAHOE, P.K., 1994. Male sex determination: current concept of male sex differentiation. *Annu Rev. Med.*, **45**: 504-524.
- GIWERCMAN, A., CARLSEN, E., KEIDING, N. AND SKAKKEBAEK, N.E., 1993. Evidence of increasing incidence of abnormalities of the Human testis. *Environ. Hlth. Perspect.*, **101**(suppl.2):65-71.
- HAYES, W.J. AND LAWS, E.R. (Eds.) 1990. *Chemistry of plant protection 4: Synthetic principles*, Vol. 1. Academic Press, Inc., NY.
- HAYES, W.J. AND LAWS, E.R. (Eds.) 1991. *Handbook of pesticide toxicology*, Vol. 2.
- HERNANDEZ, A., GOMEZ, M., PEREZ, V., GRACIALARIO, J. AND PLA, A., 2006. Influence of exposure to pesticides on serum components and enzyme activities of cytotoxicity among intensive agriculture farmers. *J. Environ. Res.*, **102**: 70-76.
- HINTON, D.E., BAUMANN, P.C., GARDENER, W.E., HAWKINS, W.E. AND HENDRICKS, J.D., 1992. Histopathologic Biomarkers. In: *Biochemical, physiological and histological markers of anthropogenic stress* (eds. R.J. Huggett, R.A. Klmerie, P.M. Mehrie and H.L. Bergman), Lewis Publishers, Boaco Rato, pp. 155-209.
- JANA-KARA, B.R., JIHULLAH, W.A., SHAHI, B., DEV, V., CURTIS, C.F. AND SHARMA, V.P., 1995. Deltamethrin impregnated bednets against *Anopheles minimus* transmitted malaria in Assam, India. *J. trop. Med. Hyg.*, **98**: 73-83.
- JENSEN, T.K., TOPPARI, J., KEIDING, N. AND SKAKKEBAEK, N.E., 1995. Do environmental estrogens contribute to the decline in male reproductive health? *Clin. Chem.*, **41**: 1896-1901.
- MCLANGLAN, J.A. AND CHEEK, A.O., 1998. Environmental hormone and the male reproductive system. *J. Androl.*, **19**: 5-10.
- MEYERS, T.R. AND HENDRICKS, J.D., 1985. Histopathology. In: *Fundamental of aquatic toxicology* (eds. G.M. Rand and S.R. Petrocelli.), Hemisphere, New York, pp. 283-331.
- PHAM, H.C., NAVARRO-DELMASURE, C., PHAM, H.C., CLAVEL, P., HAVERBEKE, AND CHEAV, S.L., 1984. Toxicological studies of deltamethrin. *Int. J. Tissue. React.*, **6**: 127-33.
- RAY, D.E., 1991. Pesticide derived from plants and other organisms. In: *Hand book of pesticide toxicology* (eds. W.J. Hayes Jr and E.R. Laws), vol. 2, pp. 585-593.
- REHMAN, H., ALI, M., ATIF, F., KAUR, M., BHATIA, K. AND RAISUDDIN, S., 2006. The modulatory effect of deltamethrin on antioxidants in mice. *Clin. Chim. Acta*, **369**: 61-65.
- SHARPE, R.M. AND SKAKKEBAEK, N.E., 1993. An estrogens involved in falling sperm counts and disorders of the male reproductive tract. *Lancet*, **341**: 1392-1395.
- SPENCER, L.T. AND BANCROFT, J.D., 2008. Microtomy: paraffin and frozen. In: *Theory and practice of histological techniques* (eds. J.D. Bancroft and M. Gamble), 6th ed. Elsevier's, Churchill Livingstone, pp. 93-104.
- TOPPARI, J., LARSAN, J.C., CHRISTIANSEN, P., GIWERCMAN, A., GRANDJEAN, P., GUILLETTE, L.J. AND JEGOU, B., 1996. Male reproductive health and environmental xenoestrogens. *Environ. Hlth. Perspect.*, **104**: 741-803.
- THE AGROCHEMICALS HANDBOOK. 1983. The Royal Society of Chemistry, The University, Nottingham, England.
- TURNER, K.J., 2002. Effects of in utero exposure to the organophosphate insecticide fenitrothion on androgen dependent reproductive development. *Toxicol. Sci.*, **68**:174-183.
- YADAV, R. S., SAMPATH, R.R. AND SHARMA, V.P., 2001. Deltamethrin treated bednets for control of malaria transmitted by *Anopheles culicifacies* (Diptera: Culicidae) in India. *J. med. Ent.*, **38**: 613-622.
- YAO, K.W. AND WANG, J.D., 2008. Progress in the studies of the male reproductive toxicity of pyrethroid insecticides. *Nat. J. Androl.*, **14**:268-271.

(Received 23 January 2012, revised 30 July 2012)

